CENTER FOR CLINICAL GUIDELINES | CANCER

Diagnostic work-up and Treatment of Salivary Gland Cancer

Version 2.0

APPROVAL
Content approval
29.04.2025 (DAHANCA)
Administrative approval
16.06.2026 (Center for Clinical Practice Guidelines | Cancer)

REVISION
Planned: 01.06.2028

KEYWORDS
DMCG, DAHANCA, Salivary Gland Cancer

Revisions to previous version (changelog)

Revisions to version 1.1

Guideline chapter	Description of revisions or additions *Please describe briefly the revisions made relevant to the chapters, to clarify which changes have been made and why)*
Title	The title as well as content have been translated into English
Recommendations	The recommendations on surgical treatment have been updated with recommendations on the surgical treatment of the neck.
Literature and evidence review	A literature search and review have been conducted to include the most recent studies and results.
Comments and considerations	The recommendations and considerations have been translated into English. The introduction has been revised and updated with presentation of the most recent epidemiological results.
References	References have been updated after literature search and review
Wording of recommendations	The recommendations on surgical treatment of the cervical lymphnodes have been updated according to national results from the DAHANCA database and results from systematic reviews. Recommendations on the histopathological evaluation have been updated according to the most recent WHO classification of head and neck cancers (from 2022). The recommendations on systemic treatment and treatment of recurrences now refers to the DHQI clinical guideline for the treatment of recurrent head and neck cancer.
Hearing and approval	This edition has been approved at DAHANCA meeting 29.04.2025.
Authors and conflicts of interest	The authors represents all head and neck cancercenters in Denmark and includes otorhinolaryngologists, oncologists, pathologists, nuclearmedicine and radiologists. There are no conflicts of interest.
Appendices	The appendices have been updated with a table describing histopathological classification of salivary gland tumours and supplementary investigations (appendix 2) as well as the most recent TNM Classification, 8th Edition (UICC 2017) (appendix 1).

Content

1. Anbefalinger – Dansk (Quick guide) 3
Udredning 3
Billeddiagnostisk udredning 3
Patologi 3
Kirurgisk behandling 4
Strålebehandling 4
Medicinsk behandling af recidiverende og/eller metastatiske spytkirteltumorer 5
Opfølgningsforløb 5
2. Recommendations English (Quick guide) 6
Diagnostic work-up 6
Diagnostic imaging 6
Pathology 6
Surgical treatment 7
Radiotherapy 7
Medical management of recurrent and/or metastatic salivary gland tumours 8
Follow-up program 8
2. Introduction 9
3. Scientific basis 12
Diagnostic work-up 12
Diagnostic Imaging 14
Pathology 16
Surgical treatment 20
Radiotherapy 25
Medical management of recurrent and/or metastatic salivary gland 29
Follow-up program 30
4. References 32
5. Method 38
6. Monitoring 41
7. Appendices 42
8. About this clinical guideline 1

1. Anbefalinger – Dansk (Quick guide)

Udredning

1. **Ved den primære kontakt skal der foretages klinisk undersøgelse, UL-skanning af halsen og, hvis det er indiceret, UL-vejledt finnålsaspiration (FNA) fra tumor (B)**

Billeddiagnostisk udredning

2. **Billeddiagnostisk udredning kan omfatte MR-skanning af hoved/hals og CT-thorax og/eller F-18 FDG PET/CT (B)**

3. **Billeddiagnostisk udredning kan suppleres med F-18 FDG PET/CT ved mistanke om metastasering eller ved recidiv (B)**

Patologi

4. **Tumorerne skal klassificeres i henhold til den til enhver tid gældende WHO-klassifikation (A)**

5. **Finnålsaspirationscytologi (FNAC), evt. suppleret med molekylærbiologisk undersøgelse, kan anvendes til præoperativ overordnet klassifikation af tumor i både de store og små spytkirtler med henblik på planlægning af operationsprocedure (B)**

6. **FNAC og frysesnit supplerer hinanden i den præoperative diagnostik (C)**

7. **Revision af spytkirteltumorer, såfremt der er behov for det, skal foretages af centerpatologer (B)**

8. **Den makroskopiske undersøgelse og udtagne snit foretages med henblik på en fyldestgørende mikroskopisk vurdering (B)**

9. **SNOMED kodning i forhold til topografi, morfologi, evt. gradering og procedure (A)**

10. **Anvendelse af specialfarvninger, immunhistokemiske undersøgelser (IHC) og molekylærbiologiske analyser efter behov. Se tabel 1, bilag 2 (A)**

Kirurgisk behandling

11. Kirurgi er den primære behandling af maligne spytkirteltumorer og operationen bør foretages på et af de onkologiske hoved-halskirurgiske centre (B)

12. Total parotidektomi bør foretages ved tumorer lokaliseret i den dybe lap, ved højmaligne tumorer, hvor risikoen for intraglandulær adenopati er stor, samt hvor der er præoperativ facialisparese (B)

13. Superficiel parotidektomi bør kun foretages hos patienter med små mobile lavmaligne tumorer lokaliseret til den superficielle lap (B)

14. Halsdissektion afhænger af tumorlokalisation og præoperativ vurdering herunder lymfeknuder på halsen (B)

15. Ved store tumorer, hvor rekonstruktion er nødvendig, skal dette om muligt foretages i forbindelse med det primære indgreb (B)

16. Nervus facialis bør bevares medmindre der er præoperativ facialisparese eller makroskopisk involvering af nerven (B)

Strålebehandling

17. Primær strålebehandling kan være indiceret ved (C):
- **Teknisk eller medicinsk inoperable patienter**
- **Patienter, som ikke ønsker operation**
- **Bevarelse af funktionalitet**

18. Postoperativ strålebehandling skal tilbydes ved (B):
- **R1/R2 sygdom**
- **T3/T4 tumorer**
- **Perineural vækst**
- **N+ sygdom**
- **Recidiv**
- **Højmalign histologi**

19. Stråledoser (B):
- **Ved primær strålebehandling gives 66-68 Gy/33-34 fraktioner mod erkendbar tumor**
- **Ved postoperativ strålebehandling gives 66 Gy ved uradikalitet**

- **Ved adjuverende postoperativ strålebehandling gives 60 Gy mod højrisikoområder**
- **50 Gy ved elektiv lymfeknudebestråling**

Medicinsk behandling af recidiverende og/eller metastatiske spytkirteltumorer

20. **Systemisk behandling af lokalavanceret og/eller dissemineret spytkirtelcancer har begrænset effekt og bør vejledes af specifik histologisk undertype og evt. tumorspecifikke targeterbare mutationer (D)**

21. **Patienter med lokalavanceret og/eller dissemineret spytkirtelcancer i god almentilstand kan henvises til genomisk udredning af targeterbare mutationer i tumor (D)**

22. **Primær systemisk behandling følger guidelines for recidivbehandling. Der henvises til SundK kliniske kvalitetsretningslinje for recidivbehandling af hoved-halskræft (D)**

Opfølgningsforløb

23. **De første fem år bør patienterne følges for evt. operabelt lokalt eller regionalt recidiv samt afhjælpning af følgevirkninger af canceren og behandlingen heraf (B)**

24. **Lokoregionale recidiver behandles i henhold til SundK kliniske kvalitetsretningslinje for recidivbehandling af hoved-halskræft (D)**

25. **Rehabilitering varetages individuelt i samarbejde med relevante tilstødende specialer samt kommunale og regionale instanser (B)**

2. Recommendations English (Quick guide)

Diagnostic work-up

1. **At the primary contact, a clinical examination, ultrasound (US) of the neck, and, if indicated, US-guided fine-needle aspiration (FNA) of the tumour should be performed (B)**

Diagnostic imaging

2. **Diagnostic imaging may include MRI of the head/neck and CT of the thorax and/or F-18 FDG PET/CT (B)**

3. **Diagnostic imaging can be supplemented with F-18 FDG PET/CT in case of suspected metastasis or recurrence (B)**

Pathology

4. **Tumours should be classified in accordance with the current WHO classification (A)**

5. **Fine needle aspiration cytology (FNAC), optionally supplemented with molecular biological analysis, can be used for pre-operative overall classification of the tumour in both major and minor salivary glands to guide surgical planning (B)**

6. **FNAC and frozen section complement each other in pre-operative diagnostics (C)**

7. **Revision of salivary gland tumours, if necessary, should be performed by specialised centre pathologists (B)**

8. **Macroscopic examination and sectioning should be carried out to enable a comprehensive microscopic assessment (B)**

9. **SNOMED coding should be applied for topography, morphology, grading (if applicable), and procedure (A)**

10. **Special stains, immunohistochemical (IHC) analyses, and molecular biological tests should be used as required. See Table 1, Appendix 2 (A)**

Surgical treatment

11. Surgery is the primary treatment modality for malignant salivary gland tumours, and the procedure should be performed at one of the oncological head and neck surgical centres (B)

12. Total parotidectomy should be performed for tumours located in the deep lobe, for high-grade malignant tumours where the risk of intraglandular lymph node involvement is high, and in cases with pre-operative facial nerve palsy (B)

13. Superficial parotidectomy should only be performed in patients with small, mobile, low-grade malignant tumours located in the superficial lobe (B)

14. Neck dissection depends on tumour location and pre-operative assessment, including the evaluation of cervical lymph nodes (B)

15. When reconstruction is needed after removal of large tumours, this should, where possible, be performed at the time of the primary procedure (B)

16. The facial nerve should be preserved unless there is pre-operative facial nerve palsy or macroscopic involvement of the nerve (B)

Radiotherapy

17. Primary radiotherapy may be indicated in the following situations (C):
- **Patients who are technically or medically inoperable**
- **Patients who decline surgery**
- **Preservation of functionality**

18. Post-operative radiotherapy should be offered in the following situations (B):
- **R1/R2 disease**
- **T3/T4 tumours**
- **Perineural invasion**
- **N+ disease**
- **Recurrence**
- **High-grade histology**

19. Radiotherapy doses (B):
- **For primary radiotherapy, 66–68 Gy in 33–34 fractions are delivered to the clinically detectable tumour**

- **For post-operative radiotherapy, 66 Gy is delivered in case of lack of radicality**
- **For adjuvant post-operative radiotherapy, 60 Gy is delivered to high-risk areas**
- **50 Gy for elective lymph node irradiation**

Medical management of recurrent and/or metastatic salivary gland tumours

20. Systemic treatment of locally advanced and/or disseminated salivary gland cancer has limited efficacy and should be guided by specific histological subtype and, where applicable, tumour-specific targetable mutations (D)

21. Patients with locally advanced and/or disseminated salivary gland cancer in good general condition may be referred for genomic profiling of tumour targetable mutations (D)

22. Primary systemic therapy follows guidelines for recurrent disease. Reference is made to the Danish Healthcare Quality Institute (DHQI) guidelines for the treatment of recurrent head and neck cancer (D)

Follow-up program

23. During the first five years, patients should be monitored for potentially operable local or regional recurrence, as well as for management of sequelae of the cancer and its treatment (B)

24. Locoregional recurrences are treated in accordance with the DHQI clinical guideline for the treatment of recurrent head and neck cancer (D)

25. Rehabilitation is provided on an individual basis in collaboration with relevant adjacent specialties, as well as municipal and regional authorities (B)

2. Introduction

Salivary gland cancer is rare, accounting for only 1-3% of all head and neck cancers. On average, there are approximately 65 new cases diagnosed in Denmark annually (1), and across the Nordic countries, age-adjusted incidence rates have remained stable over the past 30 years (1-3). It is a heterogeneous disease in terms of both anatomical localisation and histological classification. Salivary gland cancer can arise in the major salivary glands (parotid, submandibular, and sublingual glands) as well as in the minor salivary glands located in the oral cavity, nasal sinuses, pharynx, and larynx (4, 5). The most common site for salivary gland tumours is the parotid gland, but only 9-32% of tumours in the parotid gland are malignant. In contrast, 30-50% of tumours in the submandibular gland, 70-90% or more in the sublingual gland, and 50-80% of tumours in the minor salivary glands are malignant (4-8). There are no known definitive risk factors for salivary gland cancer. However, lymphoepithelial carcinomas are more frequently observed in Inuit populations than in other ethnic groups (9, 10).

Tumour localisation was reported in a nationwide study of salivary gland cancer involving 1601 patients diagnosed in Denmark between 1990 and 2015 (1), with the following findings:

- Parotid gland: 51.8%
- Submandibular gland: 12.9%
- Sublingual gland: 1.9%
- Minor salivary glands: 33.2% (of which 44.6% were located in the palate, the most common site of occurrence)

The median age at the time of diagnosis was 62 years (range 6–102 years), with a nearly equal gender distribution: men (48%) and women (52%) (1), which is consistent with previous Danish studies (2, 5, 11). The most common presenting symptom is a mass or swelling, often with a long-standing, indolent course. In a national report covering the period from 1990 to 2005, the median time from symptom onset to diagnosis was 8 months. At the time of disease onset, 41% of patients had locally advanced disease (WHO stage III-IV) (12). The vast majority of patients were in good general health (WHO performance status 0: 87%), 10% had performance status 1, and 1% had performance status 3 or 4 (2).

In the WHO classification from 2023, 21 different histological subtypes are described. There is a significant overlap in histomorphological and immunohistochemical features between the various tumour types (9). Prognosis depends on histological type and grade of malignancy. The overall prognosis following treatment of salivary gland cancer is favourable. Both Danish and international studies have reported 5-year and 10-year cause-specific survival rates of 78% and 70%, respectively (12-14), which are consistent with the results of the national report from 1990-2015, showing survival rates of 77% (CI: 75-79) and 69% (CI: 67-72), respectively (1).

Particularly for adenoid cystic carcinoma, the short-term prognosis is good, but this subtype tends to develop late distant metastases (12).

Carcinomas in the submandibular gland appear to have a higher incidence of lymph node metastases than carcinomas in the parotid gland. Tumour localisation itself is not related to distant metastasis (13), and anatomical location has not been shown to be an independent prognostic factor for survival or recurrence (1). The frequency of different histological subtypes varies according to the anatomical localisation of the primary tumour. In the Danish nationwide study, acinic cell carcinoma was the most common subtype in the parotid gland, while adenoid cystic carcinoma was most frequently found in the submandibular gland and minor salivary glands (1). Polymorphous adenocarcinoma almost exclusively occurs in the minor salivary glands (7, 9, 15). Overall, adenoid cystic carcinoma is the most common subtype in Denmark, accounting for approximately one-quarter of all salivary gland carcinomas (1).

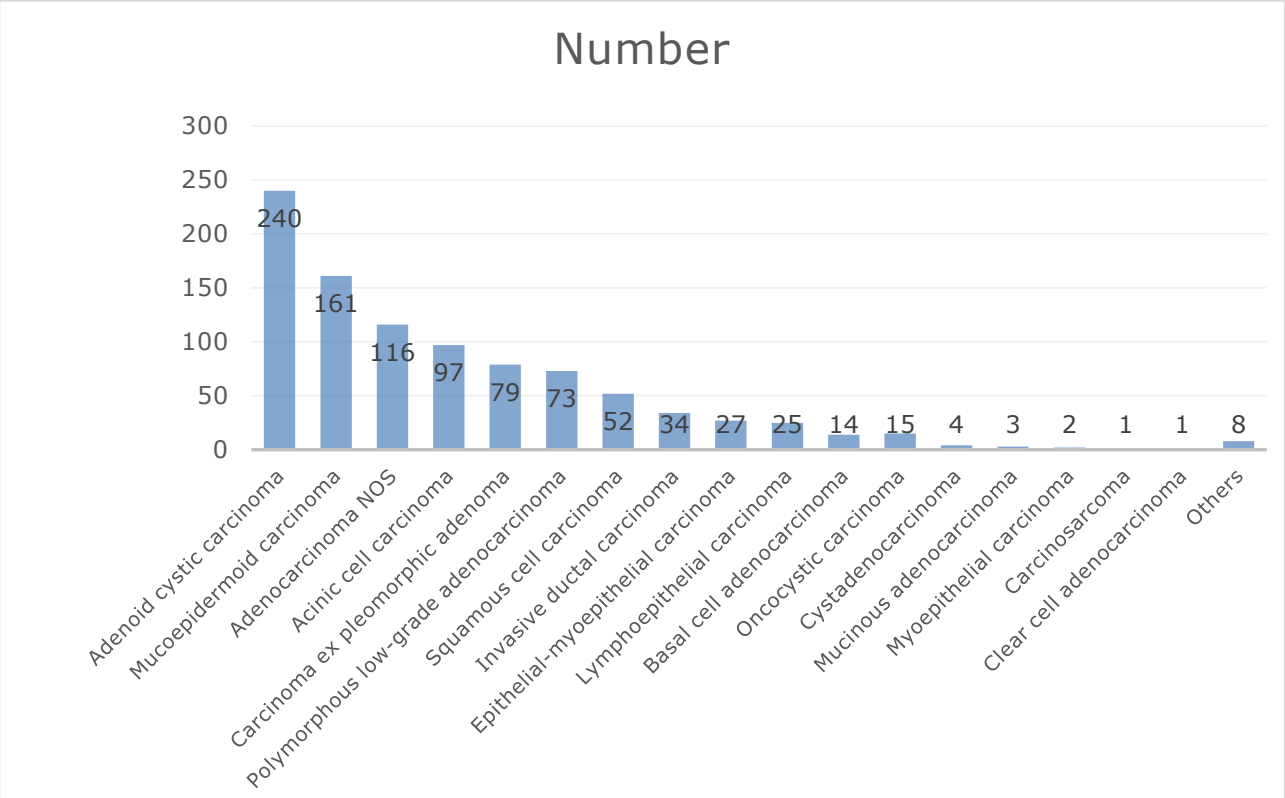

Figure 1, Histological Distribution of Salivary Gland Cancer in Denmark, 1990-2015 (data from Westergaard-Nielsen et al. (1))

Objective

The overall objective of this guideline is to support evidence-based cancer care of high and consistent quality across the Danish healthcare system.

The disease-specific guidelines should be used as evidence-based recommendations in the multidisciplinary teams involved in the management of this patient group.

Patient population

The patient group includes individuals suspected of or diagnosed with confirmed salivary gland cancer in both major and minor salivary glands. Cancer in the major salivary glands is coded as ICD 079-089. Cancer in the

minor salivary glands is coded according to anatomical localisation. Tumours are classified according to the TNM classification (Appendix 1).

Target users

This guideline is primarily developed to support clinical decision-making and quality improvement. The target users are healthcare professionals working in Danish cancer care.
This guideline is primarily intended to support clinical practice and the development of the clinical quality. Hence, the primary target audience is healthcare professionals working in clinical settings within the Danish healthcare system. The guideline is specifically aimed at otolaryngologists, oncologists, pathologists, and radiologists involved in the assessment and treatment of patients with salivary gland cancer.

3. Scientific basis

Diagnostic work-up

1. **At the primary contact, a clinical examination, ultrasound (US) of the neck, and, if indicated, US-guided fine-needle aspiration (FNA) of the tumour should be performed (B)**

Literature and Evidence Review

10 articles based on retrospective cohort studies (16-25) have been used as the basis for the recommendations. The included populations are patients with tumours of the salivary glands, primarily the parotid gland. The outcomes are sensitivity, specificity, and accuracy of fine needle aspiration (FNA) from tumours in the salivary glands or other head and neck tumours.
Westra et al. (26) is a review article that includes several retrospective studies. McGurk et al. (27) is a systematic review of 600 articles related to FNA of parotid tumours. Three of the articles consist of case reports (28-30).

Patient Values and Preferences

There is no structured information available regarding patient values and preferences related to the diagnostic process.

Rationale

Salivary gland tumours are most commonly present as a slow-growing, painless swelling. Tumours in the salivary glands are most often benign. The frequency of malignancy is unevenly distributed across the salivary glands, with the likelihood of malignancy being inversely proportional to the size of the gland.
In the case of suspected salivary gland tumour, a thorough medical history should be taken, with particular focus on pain, swelling, facial nerve palsy and possibly previous squamous cell skin tumours in the head/neck region. A standard otorhinolaryngological examination, including ultrasound (US) scan, should be performed. The clinician's diagnostic challenge is to differentiate between intra- and extra-glandular processes, inflammation, and neoplasia. In distinguishing between benign and malignant neoplasms, there are certain ultrasonographic characteristics, but a definitive differentiation is not possible. During the standard otorhinolaryngological examination and US scan, the major salivary glands are directly accessible for inspection and palpation. Lymph nodes in the neck can also be assessed. The minor salivary glands are harder to access.
Currently, there are no specific blood tests or tumour markers for salivary gland cancer.
Fine needle aspiration (FNA) should be performed when evaluating salivary gland tumours if they are accessible for sampling. This method is inexpensive, readily available, well-tolerated by patients, and minimally invasive (21, 22). The method works best in skilled hands, this applies both the sample collection and the preparation of the cell smear, as well as the interpretation of the specimen. One previous study found that 5-16% of smears were deemed not adequate for assessment (25).

When using thin needles (23-25 gauge) for FNA, no tumour seeding through the needle track has been reported, and the method is therefore considered to be very safe (28-30).
The ability to distinguish a benign process from a malignant one using fine needle aspiration (FNA) has been found to range between 81-98% in large studies, with an average sensitivity of 83% and specificity of 96%. However, the ability to make an accurate final histological subtype diagnosis using FNA from salivary glands is only around 60% (16-18, 24, 26). This suggests that it is more likely for a carcinoma to be misclassified as a benign process than for a benign tumour to be misclassified as a carcinoma.
Surgical removal of the tumour remains the first-line treatment for both benign and malignant tumours (27). It has been shown that when a pre-operative malignant diagnosis is made via FNA, it leads to improved surgical outcomes, with a higher likelihood of achieving clear resection margins (20). This has been identified as a prognostic factor for both regional and, especially, local control (13, 31). The diagnostic accuracy can be improved by combining ultrasound with FNA (19, 23).

Comments and Considerations

The parotid and submandibular glands are easily accessible for ultrasound, and any potential lymph node metastases can also be evaluated. However, the utility of ultrasound is limited by the facial skeleton, and deep structures such as parapharyngeal parotid tumours or salivary gland tumours in the palate cannot be visualised using ultrasound (32, 33).

Diagnostic Imaging

2. **Diagnostic imaging may include MRI of the head/neck and CT of the thorax and/or F-18 FDG PET/CT (B)**

3. **Diagnostic imaging can be supplemented with F-18 FDG PET/CT in cases of suspected metastasis or recurrence (B)**

Literature and Evidence Review

The above recommendation is based on literature in the form of retrospective analyses comparing the results of CT and MRI scans in patients with salivary gland tumours, specifically in terms of sensitivity and specificity (34-37). A systematic review (38) and two retrospective studies (39, 40) have been included. In general, the literature on the clinical value of FDG-PET/CT in salivary gland cancer is limited. The studies are characterised by a modest number of patients in each study, variation in disease stage, histopathology, tumour location, and study design (including the use of different imaging modalities), as well as including both primary and recurrence evaluation.
The recommendation regarding FDG-PET/CT is based on four studies from individual institutions, including two retrospective studies (41, 42) and two prospective studies (43, 44) comparing FDG-PET with CT or MRI, along with a systematic review (45) and a meta-analysis (46).

Patient Values and Preferences

There is no structured information available regarding patient values and preferences related to the diagnostic process.

Rationale

The purpose of the imaging salivary gland tumours is to define the intra- and extra-glandular extent of the tumour, identify suspicious characteristics for malignancy, assess any local extension and invasion, lymph node metastasis, and spread (38). Both CT and MRI are suitable for this imaging evaluation. If a more specific demarcation of the tumour relative to the local anatomical structures is required, MRI may be preferred (39).

Both MRI and CT are suitable for locating the retromandibular vein to differentiate between tumours in the superficial and deep lobes of the parotid gland, using the lateral boundary of the retromandibular vein as a marker for the facial nerve. The nerve itself is rarely visible on either CT or MRI (40).

In cases of adenoid cystic carcinoma, salivary duct carcinoma, low-grade mucoepidermoid carcinoma, and tumours in the submandibular gland, a CT of the thorax or PET/CT is performed due to the increased risk of lung metastases (47).
Suspected local recurrence is investigated with MRI or PET/CT, as these modalities can often distinguish between treatment-related changes and recurrent tumour tissue. PET/CT is recommended if distant metastasis is suspected.

In general, the literature on the clinical value of 18F-FDG PET and PET/CT is sparse, and the number of patients in individual studies is small. Studies have shown that PET/CT cannot differentiate between malignant and benign salivary gland lesions, partly because both Warthin's tumour and pleomorphic adenoma show increased FDG uptake without significant differences compared to carcinomas (44-46). Additionally, there is often relatively high physiological FDG uptake in normal salivary gland tissue.
However, FDG-PET/CT has proven useful for staging high-grade tumours with suspected distant metastasis and for detecting metastasis to lymph nodes during primary staging and restaging (41-45). This is supported by the current European Society for Medical Oncology (ESMO) guidelines from 2022 (48, 49).
It is concluded that MRI of the head and neck is recommended as the modality for evaluating salivary gland tumours in terms of localisation, extent, nerve involvement and lymph node metastasis. CT scanning of the head and neck is a good alternative, especially if the patient has difficulty remaining still or if MRI is contraindicated. However, dental fillings can present a significant problem when using CT.

Comments and Considerations

There are no specific comments.

Pathology

4. **Tumours should be classified in accordance with the current WHO classification (A)**

5. **Fine needle aspiration cytology (FNAC), optionally supplemented with molecular biological analysis, can be used for pre-operative overall classification of the tumour in both major and minor salivary glands to guide surgical planning (B)**

6. **FNAC and frozen section complement each other in pre-operative diagnosis (C)**

7. **Revision of salivary gland tumours, if necessary, should be performed by specialised centre pathologists (B)**

8. **Macroscopic examination and sectioning should be carried out to enable a comprehensive microscopic assessment (B)**

9. **SNOMED coding should be applied for topography, morphology, grading (if applicable), and procedure (A)**

10. **Special stains, immunohistochemical (IHC) analyses, and molecular biological tests should be used as required. See Table 1, Appendix 2 (A)**

Literature and Evidence Review

The above recommendations are based on the WHO International Classification of Tumours from 2023 (9), as well as two review articles based on level 1 and 2 studies of the molecular biological characteristics of selected subtypes of salivary gland carcinomas (50, 51), and two review articles describing histological grading and prognostic biomarkers (52, 53).

Patient Values and Preferences

It is not considered relevant in this context.

Rationale

The tumours are classified according to the current WHO classification, which includes 16 benign and 21 malignant tumours (WHO 2023). There is histomorphological diversity between tumour subtypes and within individual tumour subtypes. At the same time, some tumour subtypes exhibit histomorphological overlap, making classification challenging. Gaining sufficient experience with these tumours can be difficult. Therefore, revision of salivary gland tumours should be carried out by specialised centre pathologists.

Fine needle aspiration
Fine Needle Aspiration Cytology (FNAC) can be used for pre-operative overall classification of tumours in both major and minor salivary glands to support planning of the surgical procedure. FNAC allows the specimen to be broadly categorised as: benign salivary gland tumour, salivary gland tumour of uncertain benign or malignant nature, malignant salivary gland tumour, malignant tumour cells of uncertain primary or metastatic origin, or cyst with indeterminate morphology. Molecular biological analyses performed on cytological samples may contribute to a more specific classification.

Core needle biopsy and open biopsies
Core needle biopsies/biopsies from salivary gland tumours are most often taken from tumours originating from minor salivary glands, for example in the oral cavity, as well as from the submandibular and sublingual glands, but only rarely from the parotid gland. Malignant tumours of the minor salivary glands account for approximately one third of all malignant salivary gland tumours. Definitive tumour classification can be challenging on biopsy specimens, even when immunohistochemical studies are applied. Molecular biological analyses may contribute to a more specific pre-operative tumour classification**.**

Resected tumour
The resected tumour is sent to the Department of Pathology, where a decision is made as to whether tissue should be harvested for the biobank. The tumour should be fixated until the following day. The surface of the resection specimen may be marked with ink or another colouring agent.

Frozen section is indicated:

- In tumour classification when the results of pre-operative investigations are inconclusive, and for identification/confirmation of adenoid cystic carcinoma

- When assessing the extent of the disease, including perineural spread, lymph node involvement, and resection margins

The macroscopic description of the resection specimen should include:

- Dimensions of the resection specimen in three planes
- Tumour dimensions in three planes (at a minimum the greatest dimension)
- Distance from the tumour to the closest resection margin (to be confirmed microscopically). In cases of discrepancy between microscopic and macroscopic measurements, the microscopic measurement should be used
- Macroscopic evidence of tumour extension beyond the salivary gland
- Tumour description: solitary/multifocal (number of tumour foci should be reported), solid/cystic, tumour demarcation, presence/absence of a capsule, consistency, and the appearance and colour of the cut surface
- If a major nerve has been resected, it should be marked by the surgeon
- Presence/absence of lymph nodes within the specimen

Sampling for histological sections should include:

- Sections from the tumour with relation to the resection margins

- All identified lymph nodes should be entirely embedded in paraffin. In the case of a large, tumour-infiltrated lymph node, a full-length section should be taken and entirely embedded in paraffin
- Sections from marked nerve resection margins
- It is recommended to submit one section per 5 mm of tumour diameter, ensuring that both typical and atypical areas are represented
- Neck dissection specimens associated with salivary gland carcinomas should be handled according to current guidelines
  (See Guidelines for Oral Cavity Cancer).

The microscopic assessment should include:

- Histological classification according to the WHO Classification of Head and Neck Tumours, 2023
- Histological grade of malignancy, where applicable
- Proliferation rate assessed by Ki-67
- Presence/absence of perineural invasion
- Presence/absence of vascular invasion
- Presence/absence of a tumour capsule
- Distance to resection margins stated in millimetres. If resection margins are marked/named by the surgeon, the distance to these should be specified in the microscopic description
- Changes in macroscopically normal salivary gland tissue

SNOMED coding in relation to topography, morphology, where applicable grading, and procedure.

Special stains may be applied as required: PAS ± diastase and Alcian blue are recommended for the demonstration of glycogen, mucins, basement membrane and extracellular matrix material; PTAH is used for the identification of oncocytes.

Histological grading of malignancy

Histological grading of malignancy has been shown to be a prognostic factor, despite high inter-observer variability. Which tumours are to be graded, as well as the grading system used, depends on the current WHO classification. Grading can only be performed on resection specimens, as neither biopsies nor fine-needle aspiration cytology (FNAC) allow reliable assessment. Pre-operative assessment of malignancy is limited to salivary gland tumours, where group classification is determined solely by histological tumour type.

- Some malignant salivary gland tumours are categorised as either high-grade or low-grade based solely on histological tumour type:

Low-grade: Acinic cell carcinoma, polymorphous adenocarcinoma, microsecretory adenocarcinoma, sclerosing microcystic adenocarcinoma, intraductal carcinoma, basal cell adenocarcinoma, epithelial-myoepithelial carcinoma, secretory carcinoma, well-differentiated mucoepidermoid carcinoma, clear cell carcinoma

High-grade: Salivary duct carcinoma, predominantly squamous cell carcinoma, sebaceous adenocarcinoma, undifferentiated carcinoma (lymphoepithelial carcinoma), mucinous adenocarcinoma, carcinosarcoma, small cell neuroendocrine carcinoma, poorly differentiated mucoepidermoid carcinoma, myoepithelial carcinoma.

- Grading of adenocarcinoma not otherwise specified (NOS) and squamous cell carcinoma is based on simple anaplasia grading and is classified as low-grade, intermediate-grade, and high -grade.
- Adenoid cystic carcinoma (AdCC) is not formally graded; however, the proportion of tubular/cribriform versus solid growth patterns is assessed. Tubular–cribriform AdCC with ≤30% solid areas is associated with a better prognosis than AdCC with >30% solid growth.
- Grading of mucoepidermoid carcinoma follows the WHO classification. Tumours are stratified into low-, intermediate- and high-grade malignancy based on the proportion of solid versus cystic components, presence of necrosis, mitotic activity, cellular pleomorphism and perineural invasion.
- Carcinoma ex pleomorphic adenoma should be subclassified according to the carcinoma type. Some carcinoma types may arise *in situ* (e.g. salivary duct carcinoma). In addition, the depth of invasion of the malignant component is measured relative to the capsule of the original pleomorphic adenoma (PA) (extracapsular extension). The carcinoma is classified as non-invasive (intracapsular), minimally invasive (≤4–6 mm), or invasive (>6 mm), measured from the PA capsule.
- Some low-grade salivary gland tumours may undergo high-grade transformation, thereby becoming high-grade malignancies (e.g. acinic cell carcinoma, secretory carcinoma).
- Myoepithelial carcinoma is categorised among high-grade malignant tumours, but may show variable prognosis depending on proliferative rate, mitotic count, and the extent of necrosis.

Histological classification of salivary gland carcinomas, including stratification into surgically relevant groups, is presented in Table 1, Appendix 2. The table additionally provides an overview of diagnostic, prognostic, and any relevant predictive analyses.

Immunohistochemistry
Immunohistochemical studies (IHC) and molecular analyses are performed as indicated. See Table 1, Appendix 2.

Comments and considerations

There are no specific comments or considerations.

Surgical treatment

11. **Surgery is the primary treatment modality for malignant salivary gland tumours, and the procedure should be performed at one of the oncological head and neck surgical centres (B)**

12. **Total parotidectomy should be performed for tumours located in the deep lobe, for high-grade tumours where the risk of intraglandular lymph node involvement is high, and in cases of pre-operative facial nerve palsy (B)**

13. **Superficial parotidectomy should only be performed in patients with small, mobile, low-grade malignant tumours located in the superficial lobe (B)**

14. **Neck dissection depends on tumour location and pre-operative assessment, including evaluation of cervical lymph nodes (B)**

15. **When reconstruction is needed after removal of large tumours, this should, where possible, be performed at the time of the primary procedure (B)**

16. **The facial nerve should be preserved unless there is pre-operative facial nerve palsy or macroscopic involvement of the nerve (B)**

Literature and Evidence Review

Background for the recommendations regarding surgical treatment of T-site tumours is primarily based on retrospective series of patients with salivary gland cancer in major salivary glands (54-58) and minor salivary glands (59). The studies report institutional outcomes and include 28–98 patients, describing patient characteristics and treatment outcomes. Terhaard et al. (60, 61) report database studies investigating the prognostic significance of co-morbidity and facial nerve involvement for disease-free survival.
Clinical prognostic factors have been described in several review articles (62-64).
Regarding recommendations for surgical management of cervical lymph nodes, the literature is limited. The recommendations are based on two retrospective series (65, 66), a SEER database study (67), systematic reviews with meta-analysis (68, 69), and data from the Danish patient cohort (2006–2015) (70), which advise on treatment of cervical lymph nodes in primary cancers of major and minor salivary glands.

Patient values and preferences

Surgical treatment is always decided in consultation with the patient following comprehensive information on the risks of the procedure. Patient preferences are considered during the consultation. Common considerations include cosmetic and functional outcomes.

Rationale

Surgery is the primary treatment for malignant salivary gland tumours, and the procedure should be performed at one of the head and neck surgical centres. The extent of surgery depends on tumour location, histological subtype, and tumour stage. Radical tumour excision, and reconstruction if required, should be attempted at the primary procedure.

Parotid gland

Malignant tumours of the parotid gland are treated with parotidectomy, preserving the facial nerve where possible. Several factors must be considered to ensure an adequate surgical procedure. Therefore, a thorough pre-operative assessment is essential, including appropriate imaging, cytological evaluation, and clinical staging.

The tumour location partly determines the extent of surgery. Total parotidectomy is generally indicated for tumours located in the deep lobe, for high-grade tumours with a high risk of intraglandular lymph node involvement (54, 55), and in cases of pre-operative facial nerve palsy (56, 60). Superficial parotidectomy should only be performed in patients with small, mobile, low-grade tumours confined to the superficial lobe (57).

Submandibular gland

Treatment of malignant tumours of the submandibular gland is based on tumour size, disease stage, and histological subtype. Resection of major nerves (marginal mandibular branch, lingual nerve, and hypoglossal nerve) should only be performed in the presence of macroscopic evidence of nerve invasion.

The minor salivary glands

Approximately 80% of malignant salivary gland tumours that occur in the minor salivary glands are in the oral cavity, most frequently in the palate (1). Surgical excision with a resection margin of 5 mm or more is often sufficient. When reconstruction is needed after removal of large tumours, this should, where possible, be performed at the time of the primary procedure.

Facial nerve

In surgical resection of malignant parotid tumours, the decision to resect the facial nerve is essential. Considerations relate both to the radicality of the surgical procedure and to the potential need for nerve reconstruction in connection with the ablative intervention.

Regarding surgical radicality, the literature (57, 63) reports facial nerve involvement in up to 25% of malignant parotid tumours, and this finding has been cited as a prognostic factor for local recurrence and distant metastases (64), although no valid data exist demonstrating a significant difference in local recurrence related to facial nerve involvement.

Facial nerve involvement can occur in all histological types of salivary gland carcinoma but is most common in adenoid cystic carcinoma and mucoepidermoid carcinoma (71, 72).

Most malignant parotid tumours, like their benign counterparts, are in the superficial lobe of the gland. Most of these tumours can be resected without sacrificing nerve branches.

Both the National Comprehensive Cancer Network (NCCN) guidelines (www.nccn.org) and the European Institute of Oncology (IEO) guidelines recommend a clinical approach in which the facial nerve is preserved unless:

1. There is pre-operative facial nerve palsy.
2. There is macroscopic intraoperative involvement of the nerve, making a radical dissection of the nerve impossible.

In both cases 1) and 2), as well as all instances of microscopic nerve involvement, indicate the need for post-operative radiotherapy.

When the facial nerve is resected, most authors (58, 60, 73) advocate preforming nerve reconstruction during the same session as the ablative surgery, if feasible. Technically, nerve grafting is easier at the time of tumour ablation, when the nerve branches are fully exposed. In a few cases, direct end-to-end anastomosis may be possible, but more often grafting with nerve tissue is performed. The great auricular nerve, which lies within the surgical field, is usually suitable for this purpose. Post-operative radiotherapy, which is always indicated in cases of facial nerve involvement, may complicate any secondary reconstructive procedure.

Most authors agree that post-operative radiotherapy does not affect the outcome of primary nerve reconstruction, although a few publications argue the opposite (74).
It is essential that the surgeon performing the ablative procedure is also skilled in reconstructive nerve grafting, or that the procedure is planned within a team where both ablation and reconstruction expertise are available.

Resection margins
There are numerous publications regarding resection margins, but only a few have defined an exact measurement for a clear margin (13, 54, 75-77).
For the purposes of this guideline, resection margins are defined microscopically:

- Clear: > 5 mm
- Close/insufficient: ≤ 5 mm

Special considerations apply to margin management along the facial nerve in parotid surgery, where a clear margin of 5 mm may be difficult to achieve.

Neck dissection
The management of cervical lymph nodes in malignant salivary gland tumours is controversial, and there is no international consensus on this issue.

Parotid gland
cN+
If lymph node metastases are present at the time of diagnosis, a modified radical neck dissection should be performed, taking morbidity into consideration.

cN0
In two systematic reviews and meta-analyses of studies on lymph node metastases in patients with clinically N0 disease, the overall proportion of occult metastases was 21–25% (range 6%–65%).

The rate of occult lymph node metastases was highest in patients with T3/T4 tumours (35–36%) compared with T1/T2 tumours (15–17%), representing a 2.25-fold increased risk of occult metastases in T3/T4 tumours. Similarly, there was an increased risk of 3.76 for occult lymph node metastases in high-grade histological subtypes (32–34%) compared with low-grade tumours (9–11%) (68, 69).
Some studies recommend elective neck dissection for patients with T3/T4 tumours and/or high-grade histology. Other authors recommend elective neck dissection for all patients with parotid cancer, because pre-operative tumour classification based on FNA is unreliable, and metastases can occur even in low-grade tumours (81-84). In the Danish study of patients from 2006–2015 (77), occult lymph node metastases were found in 14% of clinically N0 patients who underwent elective neck dissection (36/259). 11% of patients with T1/T2cN0 and 22% of patients with T3/T4cN0 had occult metastases. The difference was greater when comparing low-grade tumours (9%) with high-grade tumours (27%). Level I lymph node metastases were only observed in patients with submandibular carcinoma (3 patients) and sublingual carcinoma (1 patient). No occult metastases in level I were found in patients with parotid carcinoma (70). Similarly, a systematic review found a significant difference in the risk of level I metastases between parotid cancer (15%) and submandibular cancer (71%), and recommended dissection of levels II and III for parotid cancer, with level I dissection reserved for tumours of the submandibular gland (69).

Pre-operative evaluation:
For T1/T2 cN0 tumours, neck dissection is performed at the time of tumour resection if:

- FNAC of the salivary gland tumour shows malignant cells
- There is paresis or paralysis of the facial nerve

Neck dissection is not routinely indicated in T1/T2 cN0 tumours when FNAC fails to confirm malignancy. If malignancy is confirmed histologically, an additional procedure may be performed.

For T3/T4 cN0 tumours, neck dissection is always performed. A modified neck dissection of levels II and III is carried out (69, 70). Neck dissection can also be performed as a secondary procedure if there was no suspicion of malignancy at the time of the primary surgery.

Submandibular gland
For submandibular gland cancer, elective neck dissection of levels I–III is recommended at the time of the primary surgery, except for low-grade T1 cN0 tumours (67, 70). If only a submandibulectomy has been performed initially, a secondary surgical procedure should be carried out if there is clinical or radiological evidence of residual disease (62, 65).

Minor salivary glands, including the sublingual gland
For low-grade T1 cN0 tumours in the sublingual gland or other minor salivary glands, radical surgical excision alone is sufficient, and elective neck dissection may be omitted (67). For high-grade tumours and T2–T4 tumours of the sublingual gland or minor salivary glands in the oral cavity, elective neck dissection of levels I–III is recommended (70).

Comments and considerations

There are no specific comments.

Radiotherapy

17. Primary radiotherapy may be indicated in the following situations (C):

- **Patients who are technically or medically inoperable**
- **Patients who decline surgery**
- **Preservation of functionality**

18. Post-operative radiotherapy should be offered in the following situations (B):

- **R1/R2 disease**
- **T3/T4 tumours**
- **Perineural invasion**
- **N+ disease**
- **Recurrence**
- **High-grade histology**

19. Radiation doses (B):

- **For primary radiotherapy, 66–68 Gy in 33–34 fractions are delivered to the clinically detectable tumour**
- **For post-operative radiotherapy, 66 Gy is delivered in case of lack of radicality**
- **For adjuvant post-operative radiotherapy, 60 Gy is delivered to high-risk areas**
- **50 Gy for elective lymph node irradiation**

Literature and Evidence Review

Recommendations regarding primary radiotherapy are based on retrospective analyses from individual institutions (85-87). Several studies have reported on treatment outcomes following postoperative radiotherapy (88-94). Terhaard et al. (13, 61) conducted database studies with data from 538 patients. A large study from the SEER database shows significantly better survival following postoperative radiotherapy in high-grade and locally advanced cancers of the major salivary glands (95).

Patient Values and Preferences

Radiotherapy alone can be an acceptable alternative for patients who decline surgery or when preservation of function is desired.

Rationale

Radiotherapy can be used alone or in combination with surgery and is delivered in accordance with the DAHANCA Radiotherapy Guidelines (Radiotherapy Guidelines 2020):
www.dahanca.dk/uploads/TilFagfolk/Guideline/GUID_DAHANCA_Radiotherapy_guidelines_2020.pdf

Primary radiotherapy versus post-operative radiotherapy

There are no randomised studies comparing surgery versus primary radiotherapy for malignant salivary gland tumours. Salivary gland tumours were previously thought to be relatively radioresistant, and in most cases, surgery with or without post-operative radiotherapy has been the standard treatment.
However, smaller retrospective studies and subgroup analyses have shown acceptable outcomes with primary radiotherapy. For example: Chen et al. (85) treated 45 newly diagnosed salivary gland cancer patients from 1960 to 2004 with primary radiotherapy due to technical inoperability (38%), residual tumour after resection or open biopsy (29%), medical inoperability (27%), or patient preference (7%). They achieved 5- and 10-year local control rates of 70% and 57%, respectively. Mendenhall et al. (86) treated 64 patients with inoperable tumours from 1964 to 2003 with radiotherapy alone, achieving long-term disease-free survival in approximately 20%. Terhaard et al. (87) treated 38 patients with primary radiotherapy and found 5-year local control of 50% in those receiving >66 Gy, versus 0% for lower doses.
These data indicate that radiotherapy alone can be an acceptable alternative for patients who are technically or medically inoperable, who decline surgery, or when preservation of function is desired.

Indications for post-operative radiotherapy
There are no randomised trials comparing surgery alone versus post-operative radiotherapy for malignant salivary gland tumours. Available evidence comes from series documenting practice changes with added radiotherapy, subgroup analyses, and matched-pair analyses. Garden et al. (88) analysed 166 patients with parotid cancer and positive margins, extracapsular spread, perineural invasion, or lymph node metastases. All received post-operative radiotherapy with a median dose of 60 Gy. Median follow-up was 155 months. Local recurrence occurred in 29% (7 of 40 patients), of which 25 (18%) had metastatic disease but no locoregional recurrence. Chronic morbidity was observed in 22% of patients, including hearing loss or soft tissue/bone necrosis/exposure. Terhaard et al. (13, 62, 87) analysed 538 patients treated in Dutch centres. Of these, 498 underwent primary surgery, and 386 received post-operative radiotherapy. The radiotherapy group had significantly larger tumours, more nodal metastases, positive margins, vascular invasion, perineural invasion, and bone invasion. For the whole cohort, 5- and 10-year local control rates were 84% and 76% after surgery alone, and 94% and 91% after combined treatment.
The subgroup analyses showed no difference with or without post-operative radiotherapy for T1–T2 tumours but significant benefit from combined treatment for T3–T4 tumours. In the cases with close margins the local control was 55% (surgery alone) vs 95% (combined, $p = 0.003$). In the cases with positive margins the local control was 44% vs 82% (combined, $p < 0.001$). In the cases with perineural invasion the 10-year local control was 60% (surgery alone) vs 88% (combined, $p = 0.01$). For the patients with nodal disease (N+) the local control was 62% (surgery alone) vs 86% (combined, $p = 0.03$). There was no significant difference in N0 disease.
Similar trends have been reported in other studies (89-91, 94).
Risk factors for locoregional recurrence include positive or close margins, perineural invasion, nodal metastases, advanced T stage, and high-grade histology (13, 92).

The largest population-based study assessing the value of adjuvant radiotherapy for high-grade and locally advanced salivary gland cancer of the major glands comes from the SEER database (95). Data from 3,714 patients were analysed. Tumour locations were parotid (80%), submandibular (17%), and sublingual (1%).
Post-operative radiotherapy reduced mortality across nearly all subgroup analyses.
In multivariate analysis, a significant reduction in mortality was observed for both high-grade and locally advanced cancers, with hazard ratios of 0.65 and 0.77, respectively.
For the minor salivary glands, retrospective data similarly support the benefit of post-operative radiotherapy (94). Regional recurrence occurred in 3 of 13 patients with nodal metastases at diagnosis.
Among N0 patients, regional metastasis was rare (<5%), regardless of elective nodal irradiation.

These series suggest that post-operative radiotherapy improves locoregional control and survival in patients with:

- R1/R2 disease (incomplete resection; special considerations apply to margin management near the facial nerve in parotid surgery)
- T3/T4 tumours
- Perineural invasion
- N+ disease (lymph node metastases)
- Recurrence
- High-grade histology (see pathology section)

There is no evidence that post-operative radiotherapy improves locoregional control or survival in low-grade T1–T2 tumours (92, 94).
Recent data suggest that for low- or intermediate-grade tumours with radical resection and close microscopic margins (>1 mm), it may be reasonable to consider omitting post-operative radiotherapy (96-98).

Technique, dose and fractionation
Prior to radiotherapy, tumour site preparation is performed in accordance with the DAHANCA guidelines. For a detailed description of the techniques and definitions, refer to the DAHANCA Head and Neck Radiotherapy Guidelines (www.dahanca.dk).
Primary radiotherapy: 66–68 Gy in 33–34 fractions to macroscopic tumour, delivered 5 fractions per week.
Post-operative radiotherapy: 66 Gy for macro- or microscopic disease.
Adjuvant post-operative radiotherapy (for high-risk indications): 60 Gy to high-risk regions 50 Gy to elective nodal areas.
The potential benefit of accelerated fractionation or hyperfractionation in primary radiotherapy has not been established.

Target Definitions
Reference is made to the DAHANCA Head and Neck Radiotherapy Guidelines (www.dahanca.dk)

In primary radiotherapy, lymph nodes are treated according to the same principles as described for surgery. In post-operative radiotherapy following neck dissection for node-negative (N0) disease, elective nodal regions are not irradiated.

This is particularly relevant for salivary gland cancers with perineural spread along major named nerves, where elective treatment is delivered along the nerve branches to the skull base.

Hypoxic modification
In primary radiotherapy for squamous cell carcinomas, the hypoxic radiosensitiser nimorazole can be used according to the DAHANCA guidelines.

Chemo-radiotherapy
Chemotherapy has no role in the locoregional treatment of malignant salivary gland tumours.

Particle therapy
Neutrons have been used in the treatment of salivary gland tumours at several centres, including in a randomised study of 25 patients. The study demonstrated the potential benefit of neutron therapy for inoperable or recurrent salivary gland tumours, but an increased incidence of late toxicity was observed, and no clear survival advantage could be demonstrated (99).
Based on currently published data, there is no evidence to support the routine use of particle therapy for salivary gland cancer (100).

Comments and considerations

There are no specific comments.

Medical management of recurrent and/or metastatic salivary gland

20. **Systemic therapy for locally advanced and/or disseminated salivary gland cancer has limited efficacy and should be guided by the specific histological subtype and, where applicable, tumour-specific targetable mutations (D)**

21. **Patients with locally advanced and/or disseminated salivary gland cancer in good general condition may be referred for genomic profiling of tumour targetable mutations (D)**

22. **Primary systemic therapy follows guidelines for recurrent disease. Reference is made to the Danish Healthcare Quality Institute (DHQI) guidelines for the treatment of recurrent head and neck cancer (D)**

Patient values and preferences

Systemic treatment is decided in consultation with the patient following thorough information on the expected treatment effect and potential side effects. Patient preferences are considered during the consultation.

Rationale

Primary systemic therapy follows the guidelines for recurrent disease. Reference is therefore made to the Danish Healthcare Quality Institute guidelines for treatment of recurrent head and neck cancer (section on chemotherapy and other systemic therapy for recurrence of non–squamous head and neck cancer).

Comments and considerations

There are no specific comments.

Follow-up program

23. **During the first five years, patients should be monitored for potentially operable local or regional recurrence, as well as for management of sequelae of the cancer and its treatment (B)**

24. **Locoregional recurrences are treated in accordance with the DHQI clinical guideline for the treatment of recurrent head and neck cancer (D)**

25. **Rehabilitation is provided on an individual basis in collaboration with relevant adjacent specialties, as well as municipal and regional authorities (B)**

Literature and Evidence Review

The literature regarding the risk of recurrence in adenoid cystic carcinoma comprises a Danish study (101) and a database study including 2,611 patients from 17 different countries (EUROCARE database) (102). Shindo et al. (73) and de Bree et al. (103) are review articles describing treatment options for facial nerve reconstruction and the management of Frey's syndrome, respectively.

Patient values and preferences

Follow-up after completion of treatment for head and neck cancer is internationally recommended and well-integrated into the Danish follow-up program for head and neck cancer (104-106). Most patients prefer a structured consultation program at the specialist level, including periodic radiological examinations (107, 108), although routine use of radiological imaging is not internationally recommended and is only advised when recurrence is suspected (106, 109).

Rationale

Both local and distant recurrences occur most frequently within the first few years after diagnosis. However, late recurrences can occur, particularly distant recurrences in adenoid cystic carcinoma (AdCC) (102). In a Danish study of AdCC, distant metastases were observed up to 10.6 years after diagnosis, with a cumulative risk of 27% (18/67) and a 10-year actuarial risk of 37% (95% CI: 21–53%) (101).
Median survival for patients with primarily metastatic AdCC is approximately 3½ years (102), whereas survival after recurrent metastatic AdCC has been reported at 8.5–11 months (110) and 16 months (101). Prognosis is therefore poor after distant recurrence, and effective treatment options are lacking. This makes it ethically and clinically complex to determine whether patients with salivary gland cancer should be offered follow-up beyond 5 years. During the first five years, patients should be monitored for potentially operable local or regional recurrence, as well as for the management of sequelae related to the cancer and its treatment.

Recurrence Treatment

Locoregional recurrences should, wherever possible and taking treatment-related morbidity into account, be managed surgically. Chemotherapy and other systemic treatments should be administered in accordance with

the Danish Healthcare Quality Institute Guidelines for Recurrent Head and Neck Cancer (section on chemotherapy and other systemic therapies for recurrence of non-squamous head and neck cancer).

Rehabilitation and surgical aftercare

Physical, mental and psychosocial rehabilitation is provided on an individual basis, in collaboration with relevant medical specialties as well as local and regional healthcare services. The extent of treatment-related morbidity and sequelae of the cancer itself is assessed at oncology centres and recorded in accordance with the DAHANCA follow-up forms.

Secondary facial nerve reconstruction

In cases of persistent facial nerve palsy following parotid surgery, facial rehabilitation may be indicated depending on the patient's subjective and objective functional deficits. Both static and dynamic procedures are available. The most used techniques include sling procedures with fascia lata or muscle transposition using the temporalis muscle.

Free microvascular procedures, most often with the gracilis muscle are also an option as well as reinnervation procedures may be considered in selected cases. The choice of rehabilitation procedure should be determined on an individual basis, considering factors such as the integrity of the facial nerve following the primary ablative surgery (73).

Frey's syndrome

Frey's syndrome is characterised by erythema and sweating in the cheek and temporal region in association with food intake and salivation. The condition may occur following parotid surgery and is thought to result from aberrant regeneration of transacted parasympathetic secretomotor fibres, which reinnervate sympathetic fibres supplying the sweat glands and vasculature of the overlying skin.

The incidence of Frey's syndrome after parotidectomy approaches 100% when assessed objectively (103). Symptoms may develop months to years after surgery. Most cases do not require treatment. Symptomatic Frey's syndrome can be managed with botulinum toxin injections.

4. References

1. Westergaard-Nielsen M, Godballe C, Eriksen JG, Larsen SR, Kiss K, Agander T, et al. Salivary gland carcinoma in Denmark: a national update and follow-up on incidence, histology, and outcome. Eur Arch Otorhinolaryngol. 2021;278(4):1179-88.
2. Bjorndal K, Krogdahl A, Therkildsen MH, Overgaard J, Johansen J, Kristensen CA, et al. Salivary gland carcinoma in Denmark 1990-2005: a national study of incidence, site and histology. Results of the Danish Head and Neck Cancer Group (DAHANCA). Oral oncology. 2011;47(7):677-82.
3. Pukkala E, Martinsen JI, Lynge E, Gunnarsdottir HK, Sparen P, Tryggvadottir L, et al. Occupation and cancer - follow-up of 15 million people in five Nordic countries. Acta Oncologica (Stockholm, Sweden). 2009;48(5):646-790.
4. Barnes L, Eveson JW, Reichart P, Sidransky D. Pathology and genetics of head and neck tumours. World Health Organization Classification of Tumours. LYON: IARC; 2005.
5. Mortensen KS, Hjortlund J, Bjorndal K, Krogdal A, Godballe C. Salivary gland tumors in the County of Funen, 1984-2003. Ugeskrift for laeger. 2008;170(7):545-8.
6. Bradley PJ, McGurk M. Incidence of salivary gland neoplasms in a defined UK population. British Journal of Oral and Maxillofacial Surgery. 2013;51(5):399-403.
7. Speight PM, Barrett AW. Salivary gland tumours. Oral diseases. 2002;8(5):229-40.
8. Spiro RH. Management of malignant tumors of the salivary glands. Oncology (Williston Park). 1998;12(5):671-80; discussion 83.
9. Board WCoTE W. WHO Classification of Tumours, Head and Neck Tumours, 5th Edition. Lyon: International Agency for Research on Cancer; 2023.
10. Nielsen NH, Mikkelsen F, Hansen JP. Incidence of salivary gland neoplasms in Greenland with special reference to an anaplastic carcinoma. Acta pathologica et microbiologica ScandinavicaSection A, Pathology. 1978;86(2):185-93.
11. Jepsen OTK, Bretlau P, et al. Øre-, næse-, halssygdomme & hoved-halskirurgi: Munksgaards Forlag; 2006.
12. Bjorndal K, Krogdahl A, Therkildsen MH, Overgaard J, Johansen J, Kristensen CA, et al. Salivary gland carcinoma in Denmark 1990-2005: outcome and prognostic factors. Results of the Danish Head and Neck Cancer Group (DAHANCA). Oral oncology. 2012;48(2):179-85.
13. Terhaard CH, Lubsen H, Van der Tweel I, Hilgers FJ, Eijkenboom WM, Marres HA, et al. Salivary gland carcinoma: independent prognostic factors for locoregional control, distant metastases, and overall survival: results of the Dutch head and neck oncology cooperative group. Head & neck. 2004;26(8):681-92; discussion 92-3.
14. Wahlberg P, Anderson H, Biorklund A, Moller T, Perfekt R. Carcinoma of the parotid and submandibular glands--a study of survival in 2465 patients. Oral oncology. 2002;38(7):706-13.
15. Kimple AJ, Austin GK, Shah RN, Welch CM, Funkhouser WK, Zanation AM, et al. Polymorphous low-grade adenocarcinoma: a case series and determination of recurrence. Laryngoscope. 2014;124(12):2714-9.
16. Christensen RK, Bjorndal K, Godballe C, Krogdahl A. Value of fine-needle aspiration biopsy of salivary gland lesions. Head & neck. 2010;32(1):104-8.
17. Das DK, Petkar MA, Al-Mane NM, Sheikh ZA, Mallik MK, Anim JT. Role of fine needle aspiration cytology in the diagnosis of swellings in the salivary gland regions: a study of 712 cases. Medical principles and practice : international journal of the Kuwait University, Health Science Centre. 2004;13(2):95-106.
18. Hughes JH, Volk EE, Wilbur DC, Cytopathology Resource Committee CoAP. Pitfalls in salivary gland fine-needle aspiration cytology: lessons from the College of American Pathologists Interlaboratory

Comparison Program in Nongynecologic Cytology. Archives of Pathology & Laboratory Medicine. 2005;129(1):26-31.
19. Kraft M, Lang F, Mihaescu A, Wolfensberger M. Evaluation of clinician-operated sonography and fine-needle aspiration in the assessment of salivary gland tumours. Clinical otolaryngology : official journal of ENT-UK ; official journal of Netherlands Society for Oto-Rhino-Laryngology & Cervico-Facial Surgery. 2008;33(1):18-24.
20. Lin AC, Bhattacharyya N. The utility of fine needle aspiration in parotid malignancy. Otolaryngology--head and neck surgery : official journal of American Academy of Otolaryngology-Head and Neck Surgery. 2007;136(5):793-8.
21. Mui S, Li T, Rasgon BM, Hilsinger RL, Rumore G, Puligandla B, et al. Efficacy and cost-effectiveness of multihole fine-needle aspiration of head and neck masses. The Laryngoscope. 1997;107(6):759-64.
22. Rimm DL, Stastny JF, Rimm EB, Ayer S, Frable WJ. Comparison of the costs of fine-needle aspiration and open surgical biopsy as methods for obtaining a pathologic diagnosis. Cancer. 1997;81(1):51-6.
23. Robinson IA, Cozens NJ. Does a joint ultrasound guided cytology clinic optimize the cytological evaluation of head and neck masses? Clinical radiology. 1999;54(5):312-6.
24. Seethala RR, LiVolsi VA, Baloch ZW. Relative accuracy of fine-needle aspiration and frozen section in the diagnosis of lesions of the parotid gland. Head & neck. 2005;27(3):217-23.
25. Thomsen JB, Sorensen KB, Krogdahl AS. Fine-needle aspiration cytology in the evaluation of head and neck tumors. What is the cause of inadequate samples? Ugeskrift for laeger. 2004;166(40):3497-9.
26. Westra WH. Diagnostic difficulties in the classification and grading of salivary gland tumors. International journal of radiation oncology, biology, physics. 2007;69(2 Suppl):S49-51.
27. McGurk M, Hussain K. Role of fine needle aspiration cytology in the management of the discrete parotid lump. Annals of the Royal College of Surgeons of England. 1997;79(3):198-202.
28. Bahar G, Dudkiewicz M, Feinmesser R, Joshua BZ, Braslavsky D, Popovtzer A, et al. Acute parotitis as a complication of fine-needle aspiration in Warthin's tumor. A unique finding of a 3-year experience with parotid tumor aspiration. Otolaryngology--head and neck surgery : official journal of American Academy of Otolaryngology-Head and Neck Surgery. 2006;134(4):646-9.
29. Di Palma S, Simpson RH, Skalova A, Michal M. Metaplastic (infarcted) Warthin's tumour of the parotid gland: a possible consequence of fine needle aspiration biopsy. Histopathology. 1999;35(5):432-8.
30. Skalova A, Starek I, Michal M, Leivo I. Malignancy-simulating change in parotid gland oncocytoma following fine needle aspiration. Report of 3 cases. Pathology, research and practice. 1999;195(6):399-405.
31. Therkildsen MH, Christensen M, Andersen LJ, Schiødt T, Hansen HS. Salivary gland carcinomas--prognostic factors. Acta Oncol. 1998;37(7-8):701-13.
32. Thoeny HC. Imaging of salivary gland tumours. Cancer Imaging. 2007;7(1):52-62.
33. Gritzmann N, Rettenbacher T, Hollerweger A, Macheiner P, Hübner E. Sonography of the salivary glands. Eur Radiol. 2003;13(5):964-75.
34. Rudack C, Jörg S, Kloska S, Stoll W, Thiede O. Neither MRI, CT nor US is superior to diagnose tumors in the salivary glands--an extended case study. Head Face Med. 2007;3:19.
35. Chikui T, Shimizu M, Goto TK, Nakayama E, Yoshiura K, Kanda S, et al. Interpretation of the origin of a submandibular mass by CT and MRI imaging. Oral Surg Oral Med Oral Pathol Oral Radiol Endod. 2004;98(6):721-9.
36. de Ru JA, van Benthem PP, Hordijk GJ. The location of parotid gland tumors in relation to the facial nerve on magnetic resonance images and computed tomography scans. J Oral Maxillofac Surg. 2002;60(9):992-4; discussion 5.
37. Kurabayashi T, Ida M, Tetsumura A, Ohbayashi N, Yasumoto M, Sasaki T. MR imaging of benign and malignant lesions in the buccal space. Dentomaxillofac Radiol. 2002;31(6):344-9.

38. Lee YY, Wong KT, King AD, Ahuja AT. Imaging of salivary gland tumours. Eur J Radiol. 2008;66(3):419-36.
39. Koyuncu M, Seşen T, Akan H, Ismailoglu AA, Tanyeri Y, Tekat A, et al. Comparison of computed tomography and magnetic resonance imaging in the diagnosis of parotid tumors. Otolaryngol Head Neck Surg. 2003;129(6):726-32.
40. Divi V, Fatt MA, Teknos TN, Mukherji SK. Use of cross-sectional imaging in predicting surgical location of parotid neoplasms. J Comput Assist Tomogr. 2005;29(3):315-9.
41. Lee SH, Roh JL, Kim JS, Lee JH, Choi SH, Nam SY, et al. Detection of distant metastasis and prognostic prediction of recurrent salivary gland carcinomas using (18) F-FDG PET/CT. Oral Dis. 2018;24(6):940-7.
42. Ma S, Liu Y. Diagnostic value of fluorine-18 fluorodeoxyglucose positron emission tomography/computed tomography in sublingual and submandibular salivary gland tumors. Mol Clin Oncol. 2020;13(4):27.
43. Park MJ, Oh JS, Roh JL, Kim JS, Lee JH, Nam SY, et al. 18F-FDG PET/CT Versus Contrast-Enhanced CT for Staging and Prognostic Prediction in Patients With Salivary Gland Carcinomas. Clin Nucl Med. 2017;42(3):e149-e56.
44. Westergaard-Nielsen M, Rohde M, Godballe C, Eriksen JG, Larsen SR, Gerke O, et al. Up-front F18-FDG PET/CT in suspected salivary gland carcinoma. Ann Nucl Med. 2019;33(8):554-63.
45. Bertagna F, Nicolai P, Maroldi R, Mattavelli D, Bertoli M, Giubbini R, et al. Diagnostic role of (18)F-FDG-PET or PET/CT in salivary gland tumors: A systematic review. Rev Esp Med Nucl Imagen Mol. 2015;34(5):295-302.
46. Kong X, Li H, Han Z. The diagnostic role of ultrasonography, computed tomography, magnetic resonance imaging, positron emission tomography/computed tomography, and real-time elastography in the differentiation of benign and malignant salivary gland tumors: a meta-analysis. Oral Surg Oral Med Oral Pathol Oral Radiol. 2019;128(4):431-43.e1.
47. Schwentner I, Obrist P, Thumfart W, Sprinzl G. Distant metastasis of parotid gland tumors. Acta Otolaryngol. 2006;126(4):340-5.
48. van Herpen C, Vander Poorten V, Skalova A, Terhaard C, Maroldi R, van Engen A, et al. Salivary gland cancer: ESMO-European Reference Network on Rare Adult Solid Cancers (EURACAN) Clinical Practice Guideline for diagnosis, treatment and follow-up. ESMO Open. 2022;7(6):100602.
49. van Herpen C, Vander Poorten V, Skalova A, Terhaard C, Maroldi R, van Engen A, et al. Corrigendum to 'Salivary gland cancer: ESMO-European Reference Network on Rare Adult Solid Cancers (EURACAN) Clinical Practice Guideline for diagnosis, treatment and follow-up': [ESMO Open 7(6):100602, December 2022]. ESMO Open. 2023;8(5):101630.
50. Skálová A, Stenman G, Simpson RHW, Hellquist H, Slouka D, Svoboda T, et al. The Role of Molecular Testing in the Differential Diagnosis of Salivary Gland Carcinomas. Am J Surg Pathol. 2018;42(2):e11-e27.
51. Seethala RR, Griffith CC. Molecular Pathology: Predictive, Prognostic, and Diagnostic Markers in Salivary Gland Tumors. Surg Pathol Clin. 2016;9(3):339-52.
52. Seethala RR. Histologic grading and prognostic biomarkers in salivary gland carcinomas. Adv Anat Pathol. 2011;18(1):29-45.
53. Skalova A, Leivo I, Hellquist H, Agaimy A, Simpson RHW, Stenman G, et al. High-grade Transformation/Dedifferentiation in Salivary Gland Carcinomas: Occurrence Across Subtypes and Clinical Significance. Adv Anat Pathol. 2021;28(3):107-18.
54. Leverstein H, van der Wal JE, Tiwari RM, Tobi H, van der Waal I, Mehta DM, et al. Malignant epithelial parotid gland tumours: analysis and results in 65 previously untreated patients. Br J Surg. 1998;85(9):1267-72.

55. Boahene DK, Olsen KD, Lewis JE, Pinheiro AD, Pankratz VS, Bagniewski SM. Mucoepidermoid carcinoma of the parotid gland: the Mayo clinic experience. Arch Otolaryngol Head Neck Surg. 2004;130(7):849-56.
56. Lim YC, Lee SY, Kim K, Lee JS, Koo BS, Shin HA, et al. Conservative parotidectomy for the treatment of parotid cancers. Oral Oncol. 2005;41(10):1021-7.
57. Zbären P, Schüpbach J, Nuyens M, Stauffer E, Greiner R, Häusler R. Carcinoma of the parotid gland. Am J Surg. 2003;186(1):57-62.
58. Nouraei SA, Hope KL, Kelly CG, McLean NR, Soames JV. Carcinoma ex benign pleomorphic adenoma of the parotid gland. Plast Reconstr Surg. 2005;116(5):1206-13.
59. Paleri V, Robinson M, Bradley P. Polymorphous low-grade adenocarcinoma of the head and neck. Curr Opin Otolaryngol Head Neck Surg. 2008;16(2):163-9.
60. Terhaard C, Lubsen H, Tan B, Merkx T, van der Laan B, Baatenburg de Jong R, et al. Facial nerve function in carcinoma of the parotid gland. Eur J Cancer. 2006;42(16):2744-50.
61. Terhaard CH, van der Schroeff MP, van Schie K, Eerenstein SE, Lubsen H, Kaanders JH, et al. The prognostic role of comorbidity in salivary gland carcinoma. Cancer. 2008;113(7):1572-9.
62. Terhaard CH. Postoperative and primary radiotherapy for salivary gland carcinomas: indications, techniques, and results. Int J Radiat Oncol Biol Phys. 2007;69(2 Suppl):S52-5.
63. Witt RL. Major salivary gland cancer. Surg Oncol Clin N Am. 2004;13(1):113-27.
64. Lima RA, Tavares MR, Dias FL, Kligerman J, Nascimento MF, Barbosa MM, et al. Clinical prognostic factors in malignant parotid gland tumors. Otolaryngol Head Neck Surg. 2005;133(5):702-8.
65. Kaszuba SM, Zafereo ME, Rosenthal DI, El-Naggar AK, Weber RS. Effect of initial treatment on disease outcome for patients with submandibular gland carcinoma. Arch Otolaryngol Head Neck Surg. 2007;133(6):546-50.
66. Armstrong JG, Harrison LB, Thaler HT, Friedlander-Klar H, Fass DE, Zelefsky MJ, et al. The indications for elective treatment of the neck in cancer of the major salivary glands. Cancer. 1992;69(3):615-9.
67. Lloyd S, Yu JB, Ross DA, Wilson LD, Decker RH. A prognostic index for predicting lymph node metastasis in minor salivary gland cancer. International journal of radiation oncology, biology, physics. 2010;76(1):169-75.
68. Westergaard-Nielsen M, Rosenberg T, Gerke O, Dyrvig AK, Godballe C, Bjørndal K. Elective neck dissection in patients with salivary gland carcinoma: A systematic review and meta-analysis. J Oral Pathol Med. 2020;49(7):606-16.
69. Yan F, Lao WP, Nguyen SA, Sharma AK, Day TA. Elective neck dissection in salivary gland malignancies: Systematic review and meta-analysis. Head Neck. 2022;44(2):505-17.
70. Westergaard-Nielsen M, Godballe C, Grau Eriksen J, Larsen SR, Kiss K, Agander T, et al. Surgical treatment of the neck in patients with salivary gland carcinoma. Head Neck. 2021;43(6):1898-911.
71. Shang J, Sheng L, Wang K, Shui Y, Wei Q. Expression of neural cell adhesion molecule in salivary adenoid cystic carcinoma and its correlation with perineural invasion. Oncol Rep. 2007;18(6):1413-6.
72. Luo XL, Sun MY, Lu CT, Zhou ZH. The role of Schwann cell differentiation in perineural invasion of adenoid cystic and mucoepidermoid carcinoma of the salivary glands. Int J Oral Maxillofac Surg. 2006;35(8):733-9.
73. Shindo M. Management of facial nerve paralysis. Otolaryngol Clin North Am. 1999;32(5):945-64.
74. Pillsbury HC, Fisch U. Extratemporal facial nerve grafting and radiotherapy. Arch Otolaryngol. 1979;105(8):441-6.
75. Garden AS, Weber RS, Morrison WH, Ang KK, Peters LJ. The influence of positive margins and nerve invasion in adenoid cystic carcinoma of the head and neck treated with surgery and radiation. Int J Radiat Oncol Biol Phys. 1995;32(3):619-26.

76. Kokemueller H, Swennen G, Brueggemann N, Brachvogel P, Eckardt A, Hausamen JE. Epithelial malignancies of the salivary glands: clinical experience of a single institution-a review. Int J Oral Maxillofac Surg. 2004;33(5):423-32.
77. Kokemueller H, Brueggemann N, Swennen G, Eckardt A. Mucoepidermoid carcinoma of the salivary glands--clinical review of 42 cases. Oral Oncol. 2005;41(1):3-10.
78. Ali S, Palmer FL, DiLorenzo M, Shah JP, Patel SG, Ganly I. Treatment of the neck in carcinoma of the parotid gland. Ann Surg Oncol. 2014;21(9):3042-8.
79. Klussmann JP, Ponert T, Mueller RP, Dienes HP, Guntinas-Lichius O. Patterns of lymph node spread and its influence on outcome in resectable parotid cancer. European Journal of Surgical Oncology. 2008;34(8):932-7.
80. De Brito Santos IR, Kowalski LP, Cavalcante de Araujo V, Flavia Logullo A, Magrin J. Multivariate analysis of risk factors for neck metastases in surgically treated parotid carcinomas. Archives of Otolaryngology - Head and Neck Surgery. 2001;127(1):56-60.
81. Zbären P, Schüpbach J, Nuyens M, Stauffer E. Elective neck dissection versus observation in primary parotid carcinoma. Otolaryngol Head Neck Surg. 2005;132(3):387-91.
82. Stenner M, Molls C, Luers JC, Beutner D, Klussmann JP, Huettenbrink KB. Occurrence of lymph node metastasis in early-stage parotid gland cancer. Eur Arch Otorhinolaryngol. 2012;269(2):643-8.
83. Nobis CP, Rohleder NH, Wolff KD, Wagenpfeil S, Scherer EQ, Kesting MR. Head and neck salivary gland carcinomas--elective neck dissection, yes or no? J Oral Maxillofac Surg. 2014;72(1):205-10.
84. Stennert E, Kisner D, Jungehuelsing M, Guntinas-Lichius O, Schröder U, Eckel HE, et al. High incidence of lymph node metastasis in major salivary gland cancer. Arch Otolaryngol Head Neck Surg. 2003;129(7):720-3.
85. Chen AM, Bucci MK, Quivey JM, Garcia J, Eisele DW, Fu KK. Long-term outcome of patients treated by radiation therapy alone for salivary gland carcinomas. Int J Radiat Oncol Biol Phys. 2006;66(4):1044-50.
86. Mendenhall WM, Morris CG, Amdur RJ, Werning JW, Villaret DB. Radiotherapy alone or combined with surgery for salivary gland carcinoma. Cancer. 2005;103(12):2544-50.
87. Terhaard CH, Lubsen H, Rasch CR, Levendag PC, Kaanders HH, Tjho-Heslinga RE, et al. The role of radiotherapy in the treatment of malignant salivary gland tumors. Int J Radiat Oncol Biol Phys. 2005;61(1):103-11.
88. Garden AS, el-Naggar AK, Morrison WH, Callender DL, Ang KK, Peters LJ. Postoperative radiotherapy for malignant tumors of the parotid gland. Int J Radiat Oncol Biol Phys. 1997;37(1):79-85.
89. North CA, Lee DJ, Piantadosi S, Zahurak M, Johns ME. Carcinoma of the major salivary glands treated by surgery or surgery plus postoperative radiotherapy. Int J Radiat Oncol Biol Phys. 1990;18(6):1319-26.
90. Pohar S, Gay H, Rosenbaum P, Klish D, Bogart J, Sagerman R, et al. Malignant parotid tumors: presentation, clinical/pathologic prognostic factors, and treatment outcomes. Int J Radiat Oncol Biol Phys. 2005;61(1):112-8.
91. Renehan AG, Gleave EN, Slevin NJ, McGurk M. Clinico-pathological and treatment-related factors influencing survival in parotid cancer. Br J Cancer. 1999;80(8):1296-300.
92. Chen AM, Granchi PJ, Garcia J, Bucci MK, Fu KK, Eisele DW. Local-regional recurrence after surgery without postoperative irradiation for carcinomas of the major salivary glands: implications for adjuvant therapy. Int J Radiat Oncol Biol Phys. 2007;67(4):982-7.
93. Garden AS, Weber RS, Ang KK, Morrison WH, Matre J, Peters LJ. Postoperative radiation therapy for malignant tumors of minor salivary glands. Outcome and patterns of failure. Cancer. 1994;73(10):2563-9.
94. Armstrong JG, Harrison LB, Spiro RH, Fass DE, Strong EW, Fuks ZY. Malignant tumors of major salivary gland origin. A matched-pair analysis of the role of combined surgery and postoperative radiotherapy. Arch Otolaryngol Head Neck Surg. 1990;116(3):290-3.

95. Mahmood U, Goloubeva O, Koshy M, Suntharalingam M. Adjuvant Radiation is Associated with Improved Survival in High-grade and Locally Advanced Malignant Major Salivary Gland Tumors: A Surveillance, Epidemiology, and End Results Analysis. International Journal of Radiation Oncology, Biology, Physics. 2009;75(3):S489.
96. Morand GB, Eskander A, Fu R, de Almeida J, Goldstein D, Noroozi H, et al. The protective role of postoperative radiation therapy in low and intermediate grade major salivary gland malignancies: A study of the Canadian Head and Neck Collaborative Research Initiative. Cancer. 2023;129(20):3263-74.
97. Sajisevi M, Nguyen K, Callas P, Holcomb AJ, Vural E, Davis KP, et al. Oncologic Safety of Close Margins in Patients With Low- to Intermediate-Grade Major Salivary Gland Carcinoma. JAMA Otolaryngol Head Neck Surg. 2024;150(2):107-16.
98. Geiger JL, Ismaila N, Beadle B, Caudell JJ, Chau N, Deschler D, et al. Management of Salivary Gland Malignancy: ASCO Guideline. J Clin Oncol. 2021;39(17):1909-41.
99. Laramore GE, Krall JM, Griffin TW, Duncan W, Richter MP, Saroja KR, et al. Neutron versus photon irradiation for unresectable salivary gland tumors: final report of an RTOG-MRC randomized clinical trial. Radiation Therapy Oncology Group. Medical Research Council. Int J Radiat Oncol Biol Phys. 1993;27(2):235-40.
100. Lodge M, Pijls-Johannesma M, Stirk L, Munro AJ, De Ruysscher D, Jefferson T. A systematic literature review of the clinical and cost-effectiveness of hadron therapy in cancer. Radiother Oncol. 2007;83(2):110-22.
101. J Johansen OH, K Jørgensen, PP Clausen. Results of surgery +/- radiotherapy of adenoid cystic carcinoma. Clin Otolaryngol. 1995;20:188.
102. Ciccolallo L, Licitra L, Cantú G, Gatta G. Survival from salivary glands adenoid cystic carcinoma in European populations. Oral Oncol. 2009;45(8):669-74.
103. de Bree R, van der Waal I, Leemans CR. Management of Frey syndrome. Head Neck. 2007;29(8):773-8.
104. Pagh A, Vedtofte T, Lynggaard CD, Rubek N, Lonka M, Johansen J, et al. The value of routine follow-up after treatment for head and neck cancer. A national survey from DAHANCA. Acta Oncol. 2013;52(2):277-84.
105. Digonnet A, Hamoir M, Andry G, Vander Poorten V, Haigentz M, Jr., Langendijk JA, et al. Follow-up strategies in head and neck cancer other than upper aerodigestive tract squamous cell carcinoma. Eur Arch Otorhinolaryngol. 2013;270(7):1981-9.
106. Sundhedsstyrelsen. Opfølgningsprogram for hoved- og halskræft. http://wwwsstdk. 2015;1.0.
107. Mueller SA, Riggauer J, Elicin O, Blaser D, Trelle S, Giger R. Patients' preferences concerning follow-up after curative head and neck cancer treatment: A cross-sectional pilot study. Head Neck. 2019;41(7):2174-81.
108. Meregaglia M, Cairns J, Alfieri S, Favales F, Mazzitelli D, Orlandi E, et al. Eliciting Preferences for Clinical Follow-Up in Patients with Head and Neck Cancer Using Best-Worst Scaling. Value Health. 2017;20(6):799-808.
109. Simo R, Homer J, Clarke P, Mackenzie K, Paleri V, Pracy P, et al. Follow-up after treatment for head and neck cancer: United Kingdom National Multidisciplinary Guidelines. J Laryngol Otol. 2016;130(S2):S208-s11.
110. Airoldi M, Pedani F, Succo G, Gabriele AM, Ragona R, Marchionatti S, et al. Phase II randomized trial comparing vinorelbine versus vinorelbine plus cisplatin in patients with recurrent salivary gland malignancies. Cancer. 2001;91(3):541-7.

5. Method

The work process has been anchored in the multidisciplinary DAHANCA cancer group (the Danish Head and Neck Cancer Group). A multidisciplinary working group, representing all relevant specialties in the diagnosis, treatment, and follow-up of patients with salivary gland cancer, was convened to ensure representation from all Danish regional head and neck oncology centres.
The previous version of these guidelines was published in 2010 and transferred to the DMCG template in 2018. This transfer involved editorial formatting only, without updating the content. The guidelines have now undergone a comprehensive revision, as outlined below.

Literature search

This guideline is based on both national and international scientific literature. Relevant literature was identified and selected through systematic searches of databases such as Medline (https://www.ncbi.nlm.nih.gov/pubmed/) and the Cochrane Database of Systematic Reviews. The search was further supplemented with textbooks, existing guidelines available online, university library resources, and congress or conference proceedings. No time restrictions were applied in the identification of scientific evidence.

Literature review and Formulation of the recommendations

The retrieved articles, as well as other relevant publications, were distributed among the working group members for review during meetings and via online communication.

Stakeholder involvement

The guidelines have been submitted to the relevant medical specialties in Denmark. The working group includes representatives from all Danish head and neck oncology centres, as well as all specialties involved in the diagnosis and management of salivary gland cancer.

Hearing and Approval

The guideline has been approved by the DAHANCA group.

Recommendations that entail significant additional costs

The current guideline for diagnosis, treatment, and follow-up falls within the framework of the existing healthcare system, and it is therefore assessed that none of the recommendations incur significant additional costs.

Need for further research

Salivary gland cancer is a rare malignancy, covering a heterogeneous group of subtypes with varying malignant potential and prognosis. The wide variation in histological subtypes, combined with the relatively small number of patients across all age groups, makes it challenging to obtain sufficient data regarding epidemiology, histopathology, treatment and prognosis. Prospective studies with randomised comparisons of

surgery versus primary radiotherapy have not been conducted. Consequently, current knowledge on the management of salivary gland cancer is primarily based on retrospective series.

Authors and conflicts of interest

Name	Specialty	Hospital
Chair of the working group Marie Westergaard-Nielsen Senior consultant surgeon, PhD	Otorhinolaryngology	Odense University Hospital
Kristine Bjørndal Professor, senior consultant surgeon	Otorhinolaryngology	Odense University Hospital
Tejs Ehlers Klug Senior consultant surgeon, DrMedSc	Otorhinolaryngology	Aarhus University Hospital
Christina Caroline Plaschke Senior consultant surgeon, PhD	Otorhinolaryngology	Copenhagen University Hospital - Rigshospitalet
Henrik Jacobsen Senior consultant surgeon	Otorhinolaryngology	Aalborg University Hospital
Jørgen Johansen Senior consultant, PhD	Oncology	Odense University Hospital
Jesper Grau Eriksen Professor, senior consultant	Oncology	Aarhus University Hospital
Claus Andrup Kristensen Senior consultant, PhD	Oncology	Copenhagen University Hospital - Rigshospitalet
Christian Maare Senior consultant, PhD	Oncology	Herlev Hospital
Maria Andersen Senior consultant	Oncology	Aalborg University Hospital
Stine Rosenkilde Larsen Senior consultant	Pathology	Odense University Hospital
Katalin Kiss Senior consultant	Pathology	Copenhagen University Hospital - Rigshospitalet
Tina Klitmøller Agander Senior consultant, PhD	Pathology	Copenhagen University Hospital - Rigshospitalet
Anne Lerberg Nielsen Senior consultant	Nuclear medicine	Odense University Hospital
Lisbeth Høgedal Senior consultant	Radiology	Odense University Hospital

Plan for revision

A minor revision will be performed every 2 years with a literature search and update on recommendations on diagnostic work-up and treatment.

Version of guideline template

The guideline has been developed in the 2.5 version of the template.

6. Monitoring

Standards and indicators

The current guideline is monitored using the quality indicators agreed upon by the Danish Head and Neck Cancer Group (DAHANCA) and The Danish Healthcare Quality Institute (DHQI).

The above quality indicators are monitored annually, with publication of an annual report by DAHANCA. The data is made available to the treating departments.

7. Appendices

Appendix 1 – Anatomy and Staging

Anatomy

The salivary glands consist of major and minor salivary glands. The major salivary glands comprise three paired glands: the parotid gland, the submandibular gland, and the sublingual gland. The minor salivary glands, which are included in this programme, are distributed throughout the mucosa of the ear, nose, and throat region. The parotid gland is divided into a superficial and a deep lobe, separated by the facial nerve. Tumours arising from the deep lobe of the parotid gland may present as dumbbell-shaped tumours extending into the parapharyngeal space.

Staging

Tumours of the major salivary glands have their own TNM classification, whereas tumours of the minor salivary glands are classified according to their anatomical site, for example the oral cavity or the paranasal sinuses.

TNM Classification, 8th Edition (UICC 2017)

T – Primary tumour, clinical and pathological classification

TX	Primary tumour cannot be assessed
T0	No evidence of primary tumour
T1	Tumour ≤ 2cm in greatest dimension without extraparenchymal extension
T2	Tumour > 2cm but ≤ 4cm in greatest dimension without extraparenchymal extension
T3	Tumour >4 cm and/or tumour with extraparenchymal extension
T4a	Tumour invades skin, mandible, ear canal, and/or facial nerve
T4b	Tumour invades base of skull, and/or pterygoid plates, and/or encases carotid artery

Extraparenchymal extension is clinical or macroscopic evidence of invasion of soft tissues or nerve, except those listed under T4a and T4b. Microscopic evidence alone does not constitute extraparenchymal extension for classification purposes

N – Regional lymph nodes (cervical lymph nodes)

Clinical classification

N1	Metastasis in a single ipsilateral lymph node ≤ 3 cm in greatest dimension without extranodal extension
N2a	Metastasis in a single ipsilateral lymph node > 3 cm but ≤ 6 cm in greatest dimension without extranodal extension
N2b	Metastasis in multiple ipsilateral lymph nodes, all ≤ 6 cm in greatest dimension without extranodal extension
N2c	Metastasis in bilateral or contralateral lymph nodes, all ≤ 6 cm in greatest dimension without extranodal extension
N3a	Metastasis in a lymph node > 6 cm in greatest dimension without extranodal extension
N3b	Metastasis in a single or multiple lymph nodes with extranodal extension

Histological classification

pNX	Regional lymph nodes cannot be assessed
pN0	No regional lymph node metastasis
PN1	Metastasis in a single ipsilateral lymph node ≤ 3 cm in greatest dimension without extranodal extension
pN2a	Metastasis in a single ipsilateral < 3 cm in greatest dimension with extranodal extension, or > 3 cm but ≤ 6 cm in greatest dimension without extranodal extension
pN2b	Metastasis in multiple ipsilateral lymph nodes, all ≤ 6 cm in greatest dimension without extranodal extension
pN2c	Metastasis in bilateral or contralateral lymph nodes, all ≤ 6 cm in greatest dimension without extranodal extension
pN3a	Metastasis in a lymph node > 6 cm in greatest dimension without extranodal extension
pN3b	Metastasis in a lymph node > 3 cm in greatest dimension with extranodal extension or multiple ipsilateral, or any contralateral, or bilateral nodes with extranodal extension

The presence of skin involvement or soft tissue invasion with deep fixation/tethering to underlying muscle or adjacent structures or clinical signs of nerve involvement is classified as clinical extranodal extension

M – Distant metastases

M0	No distant metastases
M1	Distant metastases
pM1	Distant metastases microscopically confirmed

Stage

Stage 0	Tis	N0	M0
Stage I	T1	N0	M0
Stage II	T2	N0	M0
Stage III	T3	N0	M0
	T1, T2, T3	N1	M0
Stage IVA	T1, T2, T3	N2	M0
	T4a	N0, N1, N2	M0
Stage IVB	T4b	Any N	M0
	Any T	N3	M0
Stage IVC	Any T	Any N	M1

Appendix 2 – Histopathological Classification and Supplementary Investigations

Table 1 – Overview of Histopathological Classification of Salivary Gland Tumours and Supplementary Investigations

Overview of Salivary Gland Tumours				
WHO Classification	**Predominant cell types**	**Diagnostic markers***	**Prognostic/predictive marker**	**Histological grading**
Basal cell adenoma	Luminal and basal	Nuclear positivity for β-catenin and LEF1	Not relevant	Benign
Warthin tumour	Luminal and lymphoid	Not relevant	Not relevant	
Oncocytoma	Luminal and few basal	Not relevant	Not relevant	
Myoepithelioma	Myoepithelial	PLAG1 rearrangement (observed in 40%)	Not relevant	
Canalicular adenoma	Luminal	Not relevant	Not relevant	
Cystadenoma	Luminal and basal	Not relevant	Not relevant	
Ductal papilloma	Ductal	Not relevant	Not relevant	
Sialadenoma papilliferum	Luminal often with squamous cell morphology and basal cells	BRAF p.V600E mutation	BRAF p.V600E mutation**	
Lymphadenoma	Luminal or sebaceous and lymphoid	P16 positive	Not relevant	
Sebaceous adenoma	Sebaceous	Not relevant	Not relevant	

Intercalated duct adenoma	Luminal or myoepithelial	HRAS mutation (17%)	Not relevant	
Striated duct adenoma	Luminal, possibly basal	IDH2 mutation (100%)	Not relevant	
Sclerosing polycystic adenoma	Luminal, basal and myoepithelial	Loss of PTEN by IHC	Not relevant	
Keratocystoma	Squamous cell	RUNX2 rearrangement (100%)	Not relevant	
Sialolipoma	Adipocytes	Not relevant	Not relevant	
Pleomorphic adenoma (PA)	Luminal and myoepithelial cells	PLAG1 fusion/amplification (>50%), HMGA2 fusion/amplification (10-20%)	Not relevant	
Epithelial–myoepithelial carcinoma	Luminal and myoepithelial	HRAS-mutation (80%)	Not relevant	Low-grade
Acinic cell carcinoma (ACC)	Luminal	NR4A3 rearrangement (100%) Sox10 and DOG1 positive	Not relevant	
Secretory carcinoma	Luminal	ETV6 fusion (99%) or VIM: RET fusion (<1%) S100 og mammaglobin positive P63 og p40 negative	ETV6:**NTRK3** fusion	
Microsecretory adenocarcinoma	Basal	MEF2C:SS18 fusion (>90%) S100 og p63 positive, p40 and mammaglobin negative	Not relevant	

Pleomorphic adenocarcinoma	Basal	Classic subtype: PRKD1 mutation (80%), Cribriform subtype: PRKD Fusion (70%), s100 og p63 positive, p40 negative	Not relevant	
Hyalinising clear cell carcinoma	Basal	EWSR1 fusion (98%) PCC IHC profile + CK7	Not relevant	
Basal cell adenocarcinoma	Luminal and basal	CYLD mutation (30%) nuclear positivity for **beta-catenin** og LEF1	Not relevant	
Mucinous adenocarcinoma	Luminal	AKT1 p.E17K mutation (100%) TP53 mutation (88%), exclude metastasis	Not relevant	
Sclerosing microcystic adenocarcinoma	Luminal and myoepithelial	CDK11B mutation (casuistic)	Not relevant	
Sialoblastoma	Primitive stem cells	Most often congenital	Not relevant	
Sebaceous adenocarcinoma	Luminal sebaceous	Loss of MSH2 (10%)	Not relevant	
Adenoid cystic carcinoma (AdCC)	Luminal and myoepithelial	MYB or MYBL1 rearrangement (90%), NOTCH mutation (14%)	Solide component (≥30%)	Variable grade
Mucinous–epidermoid carcinoma (MEC)	Basal, luminal and Signet ring cells	MAML2 rearrangement (90%), CDKN2A deletion (25%)	Grading (AFIP)	
Intraductal carcinoma	Luminale og myoepiteliale	Intercalated duct subtype: RET fusion (47%), Apocrine subtype: PIK3CA or HRAS mutation (frequently seen)	Low og high grade BRAF p.V600E mutation	
Carcinoma ex pleomorphic adenoma (Ca ex PA)	Luminal, basal and myoepithelial	PLAG1 fusion/amplification (73%), TP53 mutation (60%), HMGA2 fusion/amplification (14%)	Intracapsular/minimal invasive (4-6 mm)/ invasive (>6 mm)	

Myoepithelial carcinoma	Myoepithelial	PLAG1 fusion (38%), EWSR1::ATF1 fusion (13%)	±ecrosis ki-67	
Adenocarcinoma NOS	Luminal	Diagnosis of exclusion	High grade (cystic), intermediary/low grade (ductal/glandular)	
Squamous cell carcinoma	Squamous cell	Metastasis must be excluded; presence of ductal epithelial dysplasia should be confirmed	PD-L1	High-Grade
Lymphoepithelial carcinoma	Squamous cell	EBV-EBER positive	PD-L1	
Carcinosarcoma	Luminal, basal and myoepithelial	Often Ca ex PA	Not relevant	
Invasive ductal carcinoma	Luminal	HER2 amplification (31%), AR copy gain (35%), often Ca ex PA	HER2 and AR	

8. About this clinical guideline

This clinical practice guideline is developed in collaboration between The Danish Multidisciplinary Cancer Groups (DMCG.dk) and The Danish Healthcare Quality Institute (DHQI). The development is part of an intensified guideline effort launched in relation to the National Cancer Plan IV. The aim is to support high quality cancer care across the Danish healthcare system. The guideline content is approved by the disease specific Multidisciplinary Cancer Group, whereas the format is approved by the Center for Clinical Practice Guidelines | Cancer. Further information about clinical practice guidelines concerning cancer treatment in Denmark can be found here: www.dmcg.dk/kliniske-retningslinjer

The target users of this guideline are health care professionals working in the Danish Healthcare system. The guideline consists of systematically prepared statements that can be used as a decision-making support tool by healthcare professionals and patients, when deciding on appropriate and correct care in a specific clinical situation.

Clinical practice guidelines concerning Danish cancer care is characterized as professional advice. The guidelines are not legally binding and professional judgement in the specific clinical context will always determine what the appropriate and correct medical care is. Adherence to the guideline recommendations is no guarantee for a successful outcome and sometimes care corresponding to a lower level of evidence will be preferred due to the individual patient's situation.

The clinical practice guideline contains central recommendations (chapter 1) and a description of the scientific evidence (chapters 3+4). Recommendations marked A are the strongest, whereas recommendations marked D are the weakest. For further information on strength of evidence see the "Oxford Centre for Evidence-Based Medicine Levels of Evidence and Grades of Recommendations", https://www.cebm.net/2009/06/oxford-centre-evidence-based-medicine-levels-evidence-march-2009/ Information on the target population (chapter 2) and the method of development (chapter 5) is also included in the guideline. See the table of contents for page reference.

Information on the national integrated cancer pathways – descriptions of the patient journey through the healthcare system – can be accessed at the Danish Health Authority website: https://www.sst.dk/en/disease-and-treatment/cancer/cancer-pathways

Development of this clinical practice guideline has been funded by The Danish Health Authority (National Cancer Plan IV) and The Danish Healthcare Quality Institute (DHQI).